

**PATIENT PRESENTING CLINICAL SIGNS**

Oliver Billson Grade III/VI systolic murmur. Asymptomatic. ECG – NSR.

**SPECIES ECHOCARDIOGRAPHIC FINDINGS**

Feline 2D, M-mode, and Doppler study.

**BREED** DLH  
 Left atrial size is normal. The mitral valve is normal. There is mild hypertrophy of the left ventricular posterior wall. Interventricular septal wall thickness is normal. Left ventricular internal dimensions are normal. Left ventricular systolic function is hyperdynamic. The aorta and aortic are normal. Right atrial and right ventricular dimensions are normal. The tricuspid valve is normal. The pulmonary artery and pulmonic valve are normal. No heartworms are visualized. No pericardial effusion or cardiac masses are seen.

**SEX** LA – 14.9 mm  
 LA/Ao – 1.44  
 MN IVSd – 5.4 mm  
 LVPWd – 6.5 mm  
 LVIDd – 13.9 mm  
**AGE** LVIDs – 6.1 mm  
 FS – 56%  
 6 y RA – 10.1 mm  
 LVOT – 0.90 m/s  
**WEIGHT** RVOT – 0.58 m/s  
 12.2 lb

**INTERPRETATION OF THE FINDINGS & FURTHER RECOMMENDATIONS**

Hypertrophic cardiomyopathy (HCM)

**INTERPRETED BY**

Keith Blass, DVM, MS  
 DACVIM(Cardiology)

This examination demonstrates mild hypertrophy of Oliver’s interventricular septum, consistent with an asymmetric variant of HCM. The hemodynamic effects of the hypertrophy appear to be mild, as Oliver does not have secondary dilation of his left atrium, indicating that his current risk for the development of congestive heart failure, cardiac thrombus formation, or arrhythmia formation appears to be relatively low.

**HOSPITAL NAME**

Mass Veterinary  
 Specialty Services

No reason for Oliver’s murmur is appreciated in the image set.

No therapy is recommended at this stage of disease.

**REFERRING VET**

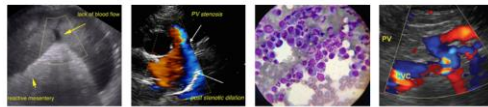
Dr. Masloski

A recheck echocardiogram is recommended in 6-9 months, sooner if new clinical signs compatible with cardiac dysfunction develop.

**INVOICE**

**DATE**

1/11/22



**PATIENT**

Oliver Billson

**SPECIES**

Feline

**BREED**

DLH

**SEX**

MN

**AGE**

6 y

**WEIGHT**

12.2 lb

**INTERPRETED BY**

Keith Blass, DVM, MS  
 DACVIM(Cardiology)

**HOSPITAL NAME**

Mass Veterinary  
 Specialty Services

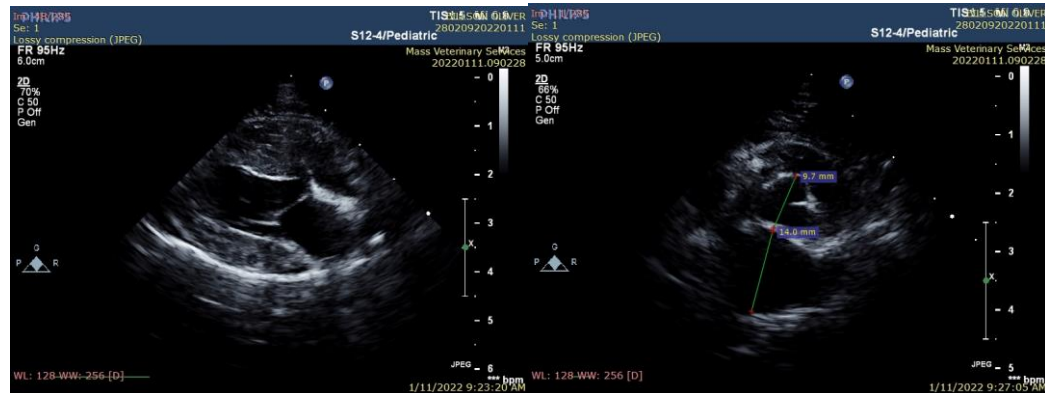**REFERRING VET**

Dr. Masloski

**INVOICE**

**DATE**

1/11/22



The information and recommendations provided are based on the images presented by the referring veterinarian. No evaluation can be communicated regarding pathology that was not visible in the image/video clips provided.

Thank you for this referral. If the clinical or image interpretation does not parallel your findings or if I can be of any further assistance please contact me.

Keith Blass, DVM, MS, DACVIM (Cardiology)

KeithBlass@gmail.com

631-804-5754